Ocular manifestations in HIV

Lily Nyamai-Kanyata
(MBChB,Mmed,FEACO)

Overview

- Why is it important to know about manifestations of HIV in the eye
- What are the common manifestations of HIV
- What to do with HIV patients to minimize eye disease
- Importance of an eye evaluation for every PLHIVA

Holistic and Systematic Approach

- Holistic approach

Push In the right direction

screening of blood donors.

Baseline studies for other infections that are important in the initial workup o patient with newly diagnosed HIV infection include the following:

- Purified protein derivative (PPD) skin testing for tuberculosis
- Cytomegalovirus (CMV) testing
- Syphilis testing
- Rapid amplification testing for gonococcal and chlamydial infection
- Hepatitis A, B, and C serology
- Anti- *Toxoplasma* antibody
- Ophthalmologic examination

What is the magnitude?

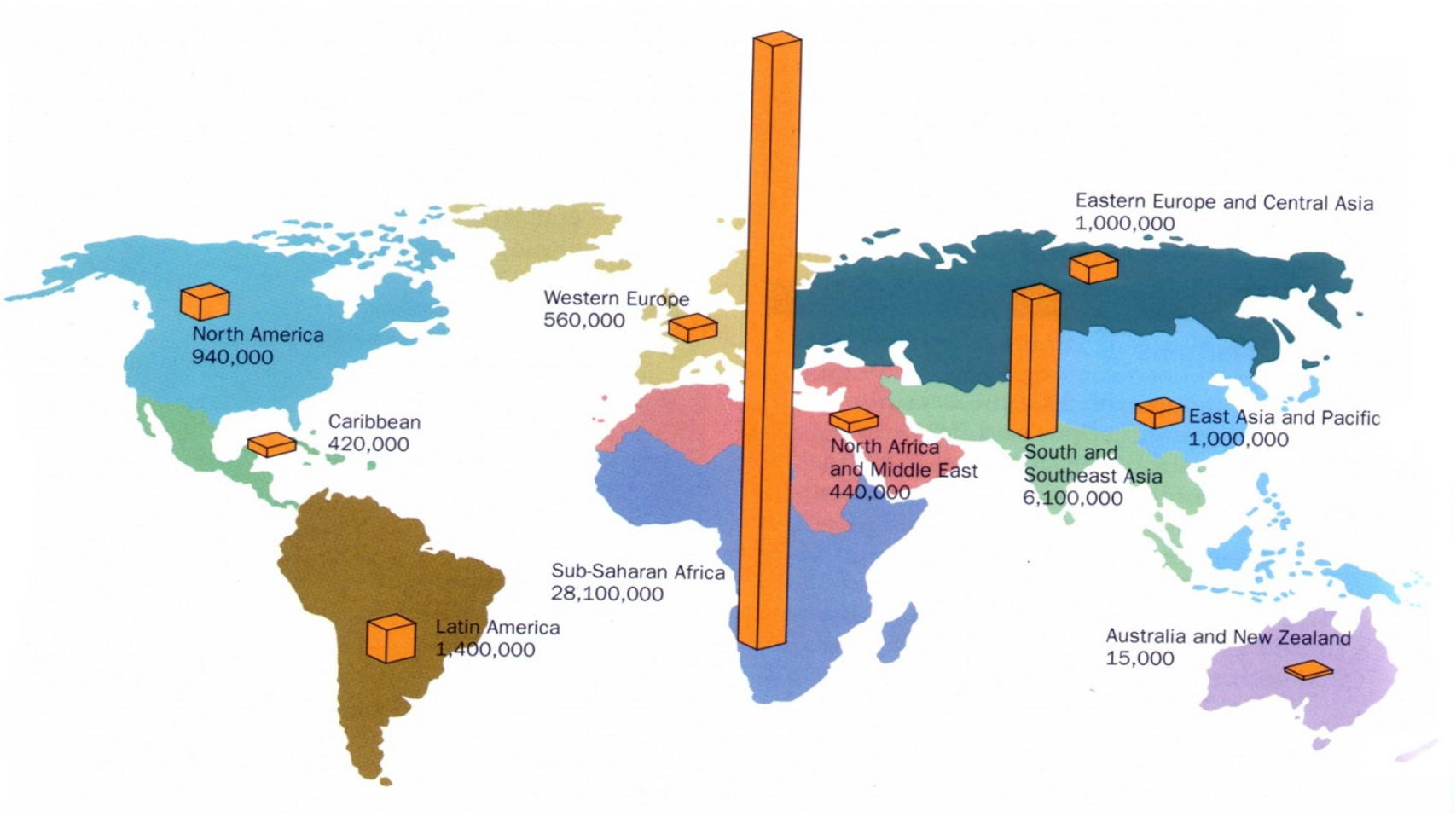

What is the magnitude?

- It is estimated that more than 70% of adult AIDS patients will experience an ocular complication at some point of the disease.
- 31% prevalence in ocular manifestations(Remezo et al, dissertation 2016)
- SSA still has a great burden of patients not on HAART

Why should PHIVA undergo routine ophthalmologic examinations?

- Proper diagnosis and treatment may help to maintain vision and prolong life
- Some retinal OI may have a rapid and devastating course.

CD 4 T-cell categorization of ocular manifestations

- $CD4^+$ T-cell count below 500/mL is associated with Kaposi sarcoma, lymphoma, and tuberculosis
- $CD4^+$ T-cell count below 250/mL is associated with pneumocystosis and toxoplasmosis

$CD4^+$ T-cell categorization of ocular manifestations

$CD4^+$ T-cell count less than 100/mL is associated with the following: Same suspects in neurological complications

- Retinal or conjunctival microvasculopathy
- Cytomegalovirus (CMV) retinitis
- Varicella-zoster virus (VZV) retinitis
- *Mycobacterium avium* complex infection
- Cryptococcosis
- Microsporidiosis
- HIV encephalopathy
- Progressive multifocal leukoencephalopathy



Anatomic Categorization of Ocular Manifestations

- **Orbital and adnexal findings:** include tumors of the periocular tissues and external infections.
- **Anterior segment manifestations** consist of keratitis, keratoconjunctivitis sicca, iridocyclitis, and other complications.
- **Posterior segment findings** include a HIV associated retinopathy and a number of opportunistic infections (OI) of the retina and choroid.
- **neuro-ophthalmic manifestations**, such as visual field defects, papilledema, and diplopia.
- Involving more than one region

Adnexal Manifestations(eyelid, the conjunctiva, and the lacrimal drainage system)

Kaposi`s sarcoma

- Kaposi sarcoma is a spindle-cell tumor thought to be derived from endothelial cell lineage.
- most common malignancy seen in HIV-infected patients
- CD4 tcell<500/ml

Adnexal Manifestations- Kaposi Sarcoma

- Treatment options
- Regression in patients on HAART
- Chemotherapy – systemic and intra-leision
- Radiation
- Excision

Adnexal Manifestations(eyelid, the conjunctiva, and the lacrimal drainage system)

Herpes Zoster Ophthalmicus

- Reactivation of latent varicella zoster virus in the ophthalmic division of the trigeminal nerve
- Unilateral painful skin rash in a dermatomal distribution

Herpes Zoster Ophthalmicus

Herpes zoster Ophthalmicus

- Ophthalmic division: lacrimal, nasociliary and frontal
- Hutchinson's sign- nasociliary branch involved
- Vesicles at the tip of the nose, look for corneal epithelial defects
- Treatment: acyclovir

Dentritic corneal ulcer in Nasociliary involvment

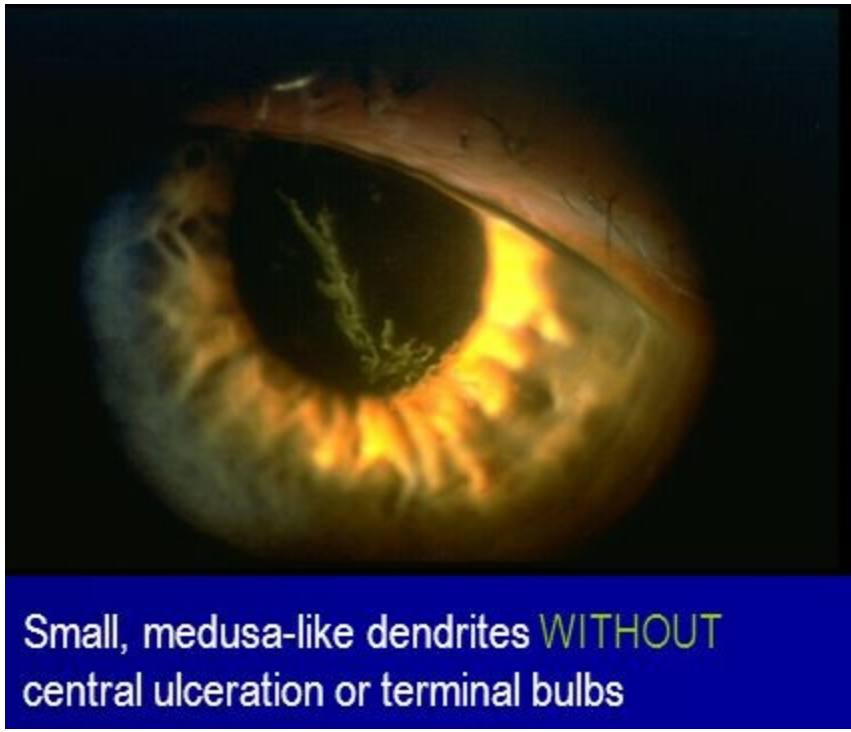

Adnexal Manifestations(eyelid, the conjunctiva, and the lacrimal drainage system)

Moluscum Contagiosum

- Cause: DNA poxvirus ,molluscu contagiosum virus (MCV).
- HIV patients: common, large leisions ,numerous and more rapidly growing.
- Pearly dome shaped umbilicate skin leisons
- self limited but may require treatment if numerous and symptomatic (e.g conjunctivitis
- Treatment options: curretage (scapping off) and cauterizing with phenol, cryotherapy, medi therapy(salicylic acid), immonotherapy and laser

Adnexal Manifestations

Conjunctival squamous-cell carcinoma

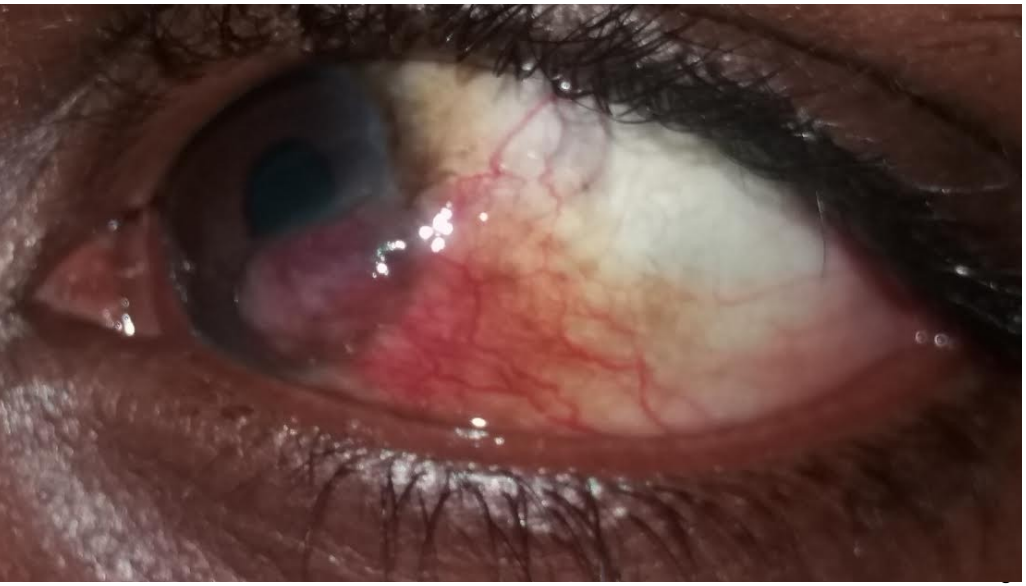

- Thought to be a rare tumour
- Early presentation is an inter-palpebral mass: gelatinous,fungating, leucoplakic, pigmented
- Feeder vessel

Adnexal Manifestations

Conjunctival Squamous Cell Carcinoma

- Diagnosis: preferably excision biopsy with margin for histology
- Treatment mainly surgical

Adnexal Manifestations- Conjunctival Microvasculopathy

Common (HIV / AIDS)

No known adverse

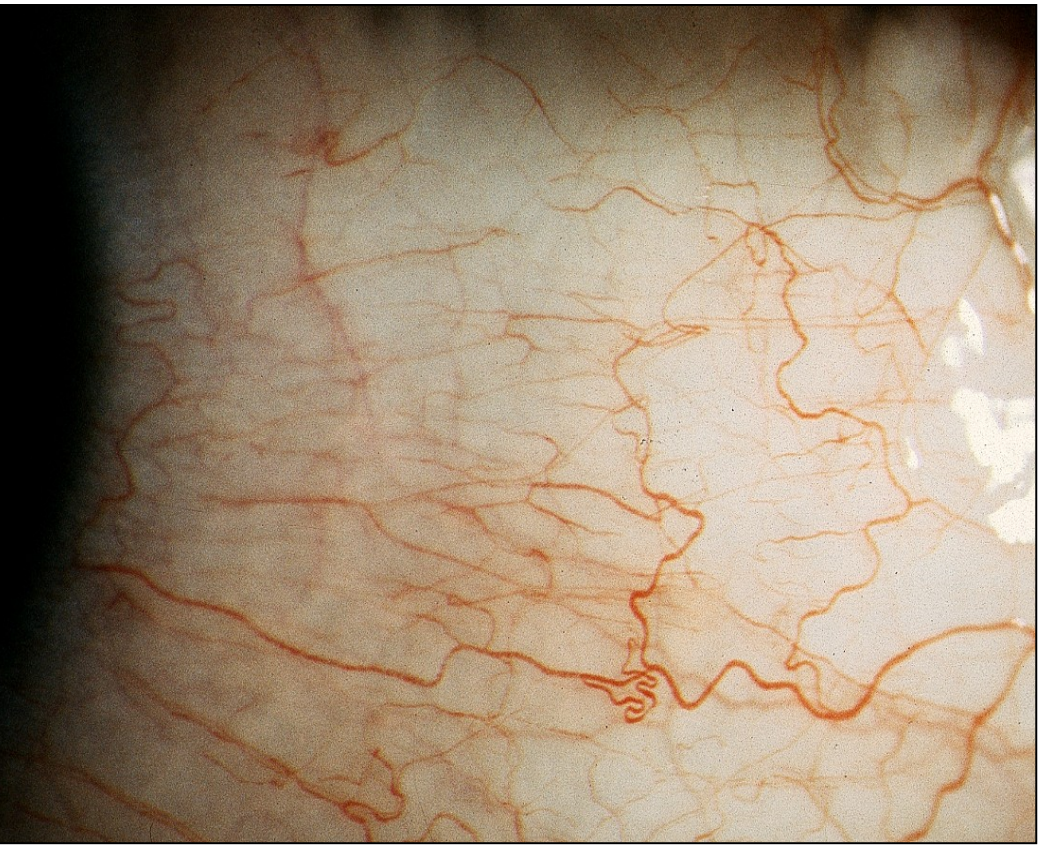

- asymptomatic microvascular changes correlated with retinal microvasculopathy

Cause?deposition of immune complexes related to HIV or the direct infection of HIV in the conjunctival vascular endothelium.

Orbital Manifestations- Orbital cellulitis

- **Orbital cellulitis**
- Organisms: Aspergillus, Rhizopus arrhizus, Toxoplasma gondii and Pneumocystis carinii.
- Children may present with recurrent episodes of orbital/peri-orbital cellulitis

Orbital Manifestations- Tumors

- Primary non-Hodgkin`s lymphoma (NHL) of the orbit and ocular adnexa
- Rare disease.
- Homogeneous isodense orbital mass molding around the lateral ocular surface
- Mold, no bone

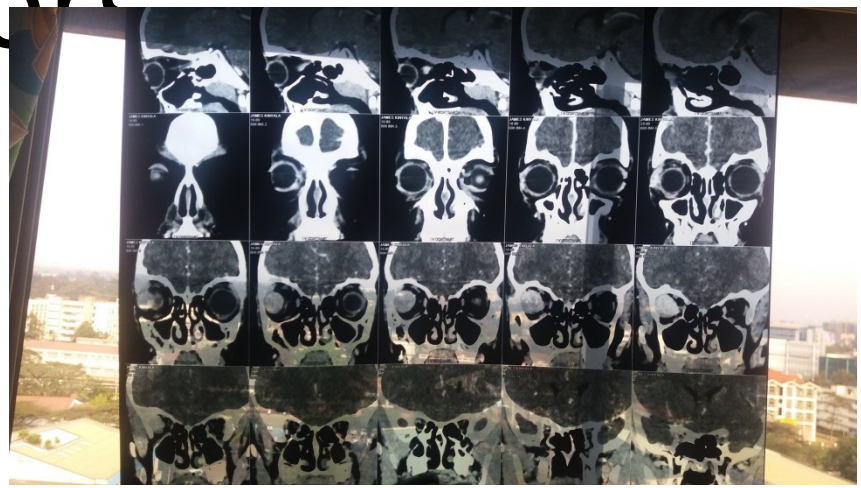

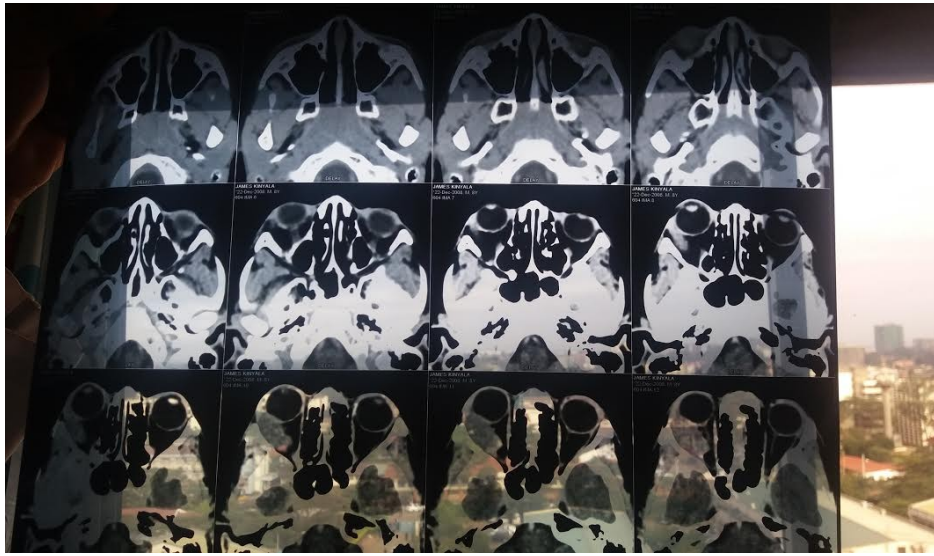

Anterior Segment Disease

- more than 50% of HIV infected patients have anterior segment manifestations.
- Keratitis, keratoconjunctivitis sicca and iridocyclitis, most common complications of ant seg disease

Anterior Segment Disease-Herpes Simplex Keratitis

- In AIDS Longer course of disease and increased rate of recurrences.
- Treat with topical acyclovir, oral acyclovir

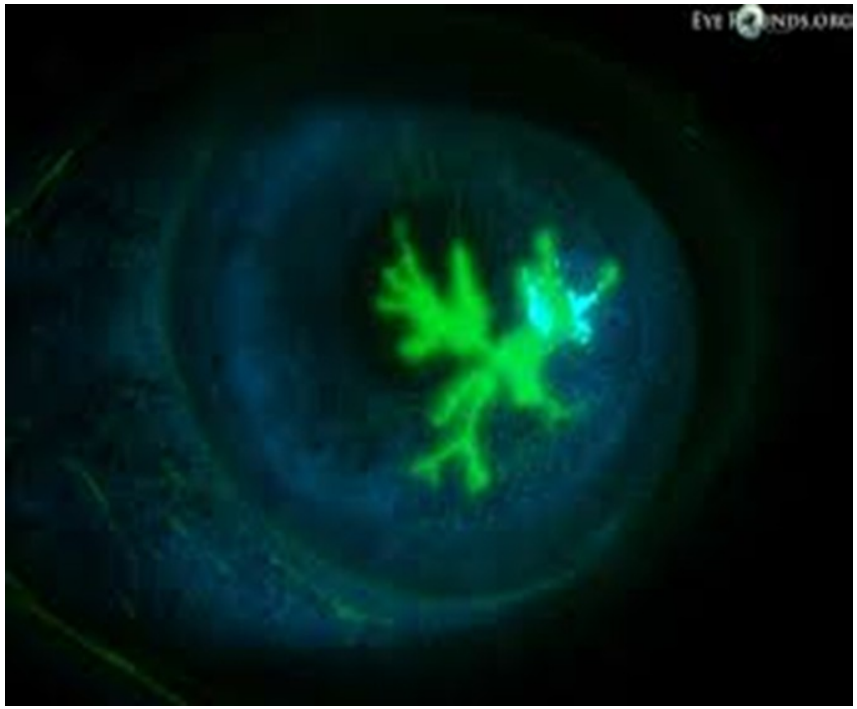

Bacterial and Fungal Corneal Infections

- Bacterial and fungal infections are generally more severe in HIV infected patients
- Spontaneous fungal keratitis

Keratoconjuctivitis Sicca

- A.k.a dry eye syndrome, which results from deficiency of any of the tear film layers
- A case control study done in KNH in 2015 showed 30.2% of PLHIVA in KNH had DES
- Symptoms: foreign body sensations, photophobia and decreased visual acuity.
- Cause:destruction of lacrimal glands and inflammation mediated by the HIV virus.
- Treatment is lubricants

Iridocyclitis/uveatis

- photophobia and red eye.
- Same symptoms manifest in anterior or posterior segmen disease.
- Proper eye examination
- Infections: syphilis, toxoplasmosis
- Medications: rifabutin and cidofovir
- Immune recovery uveatis
- Reiter`s syndrome, classic triad of arthritis, urethritis, and conjunctivitis.
- Treat cause , steroids

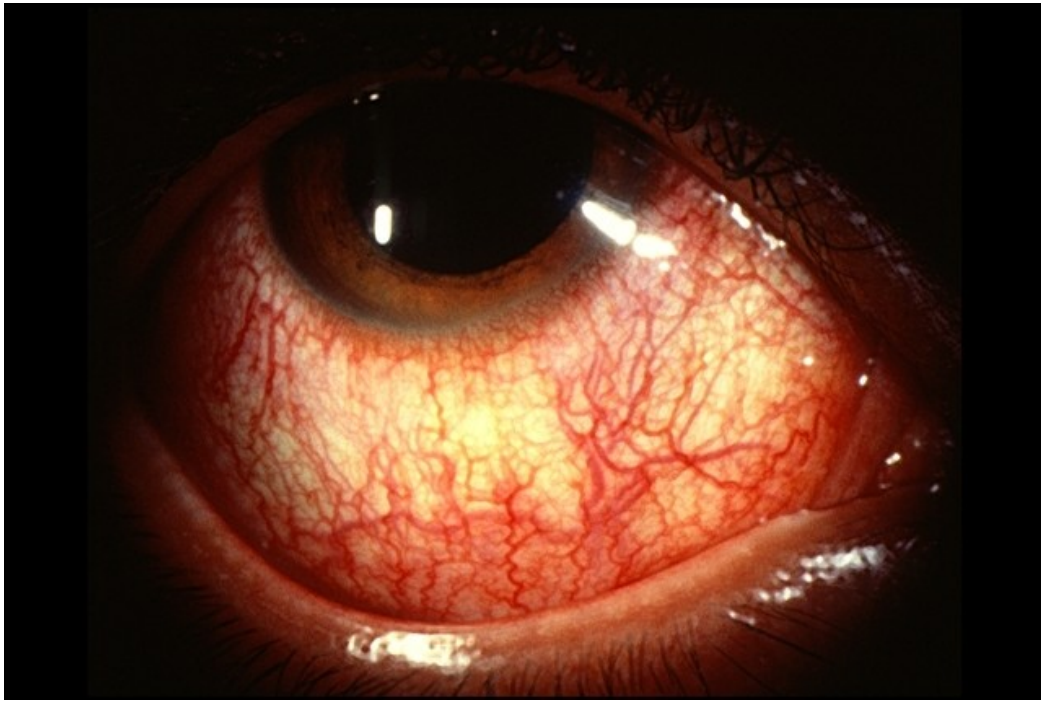

Retinal Microvasculopathy

- Most common ocular manifestation (AIDS)-70%
- Patho-mechanism:
  - deposition (HIV-related immune complexes)
  - direct infection (vascular endothelium)
  - increased plasma viscosity
  - combination?
- Presentaton: Assymptomatic,Cotton wool spots, intraretinal haemorrhages, retinal microaneurysms
- Marker for severely compromised immune status:
  - inversely related to CD4+ cell count
  (≈ 50% of patients with CD4+ ≤ 50 cells/µl)
  - risk of opportunistic infections, 3/12 follow up!

Retinal Microvasculopathy

- Different from CMV: do no affect visual acuity, CWS are smaller, do not progress and resolve
- AIDS patients with CWS should have close follow up.

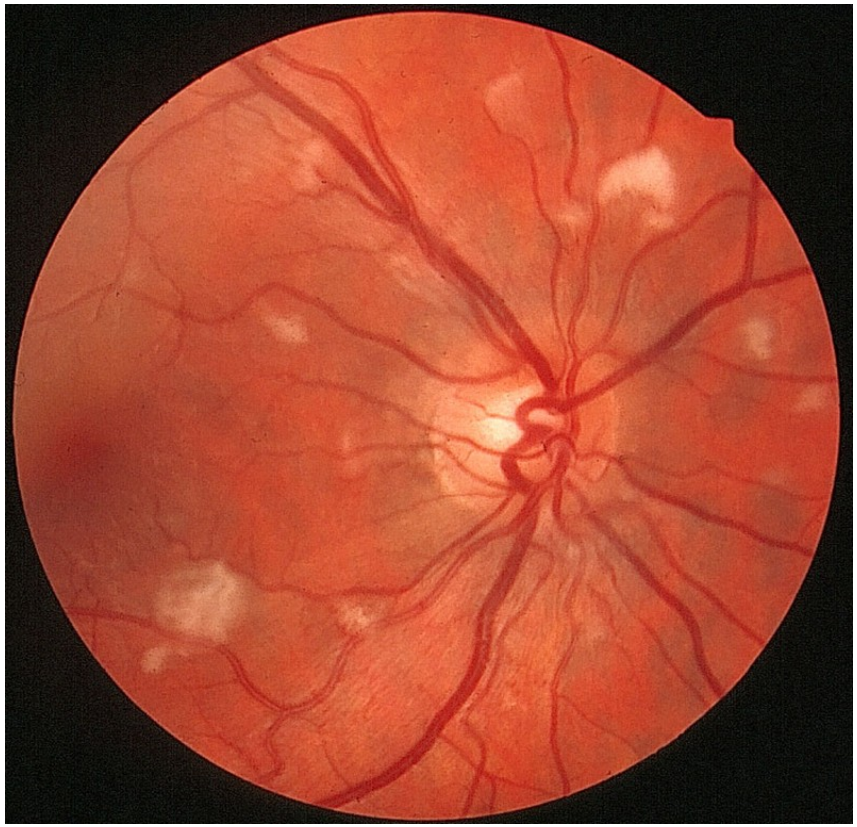

Infectious Retinitis

- Most common: Syphilis, candida, varicella-zoster, toxoplasmosis, herpes simplex and cytomegalovirus (CMV) retinitis are most common ones.
- Course of disease is longer in AIDS patients, and higher rate of recurrences.

OPPORTUNISTIC INFECTIONS
(RETINA)

- Cytomegalovirus (HCMV retinitis)
- Herpes simplex virus (ARN)
- Varizella zoster virus (ARN, PORN)
- Treponema pallidum (chorio-retinitis)
- Candida albicans (endophthalmitis)
- Staph. aureus ... (endophthalmitis)

Varicella Zoster Virus

- Varicella zoster virus associated with **acute retinal necrosis (ARN)**
- Presentation: peripheral retinal whitening, intraretinal hemorrhages, rapidly progressing necrosis,
- Complication:Retinal detachment with proliferative vitreoretinopathy,
- involvement of the other eye may also occur.(58, 59)

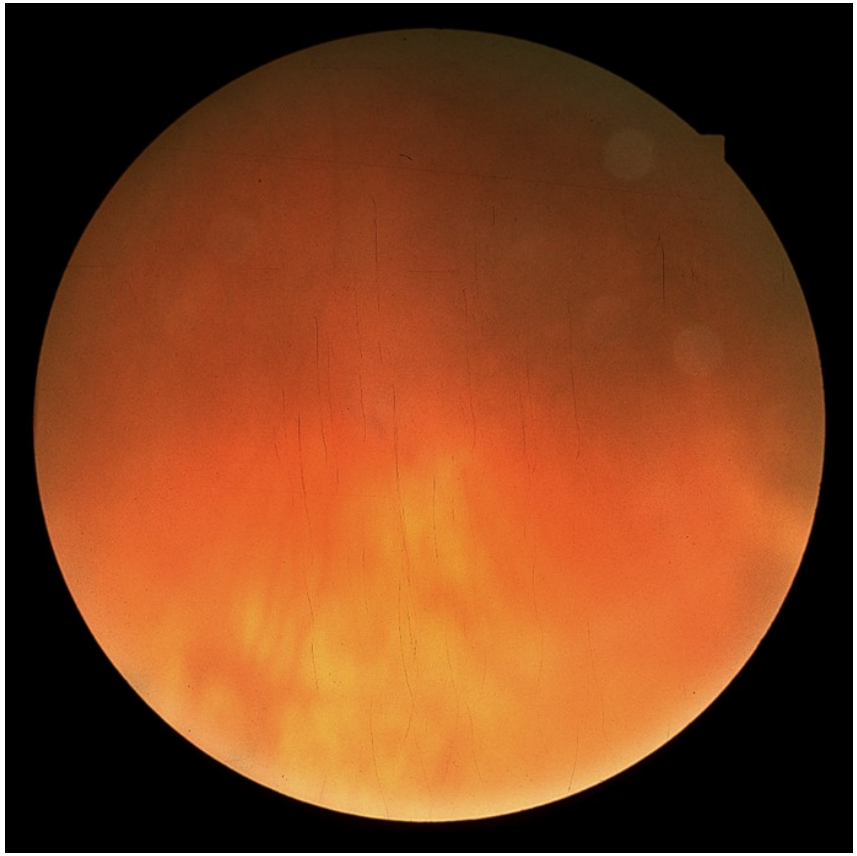

Cytomegalovirus(CMV) Retinitis

- CMV retinitis is the mos common intraocular infection related to HIV infection
- beta subgroup of herpe viruses (Herpes viridae
- CD4 tcell count 50 less
- Infection is usually subclinical in immunocompetent hos
- In PLHIVA, CMV may lead to several complications

CMV retinitis

- Symptoms: reduced V.V, floaters, scotom
- Signs:yellow white retinal lesions, retina hemorrhages
- Complications: retin detachment
- intravenous (IV), ora and intravitreal medications

CMV Retinitis

Intravenous (IV), oral, ar
intravitreal medications.

- 1. Oral valganciclovir
- 2. Intravenous ganciclovir
- 3. Intravenous foscarnet
- 4. Intravenous Cidofov
- 5. Intraocular ganciclovir device

CMV retinitis

- The game changer HAART
- decrease in the incidence and prevalence of CMV retinitis after the advent of HAART.
- Fewer relapses
- Decreased progression, increased remission,
- Close followup because relapse may occur.

Neuro-Ophthalmic Manifestations of HIV Infection

- Include: optic neuropathies, Nerve palsies, optic neuritis, homonymous hemianopia and nystagmus, papilloedema
- Optic neuropathies related compression,infiltration, infection, vaso occlusion or inflammation.
- Nerve palsies: Cryptococcal meningitis and intracerebral toxoplasma cysts
- Multiple Sclerosis: optic neuritis
- SOL ,Progressive multifocal leukoencephalopathy-homonymous hemianopia and nystagmus
- Herpes virus may present with papilledema and extraocular muscle palsies.
- Inv: Lumbar puncture, MRI

Role of highly active antiretroviral therapy (HAART),

- dramatically improved the prognosis of HIV infection.
- Spontaneus resolution
- substantial intraocular inflammation in patients with healed cytomegalovirus retinitis receiving HAART has been reported, which is known as **immune recovery uveitis**.

Summary

- PLHIVA deserve an opthalmologic review
- Know and practice your HIV medicine well
- If in doubt refer or call the ophthalmologist

References

- http://www.djo.harvard.edu/site.php?url=/physicians/oa/674

Thank you for being such a wonderful audience